

LIGHT-INDUCED RETINAL DAMAGE USING DIFFERENT LIGHT SOURCES, PROTOCOLS AND RAT STRAINS REVEALS LED PHOTOTOXICITY

A. KRIGEL, M. BERDUGO, E. PICARD, R. LEVY-BOUKRIS, I. JAADANE, L. JONET, M. DERNIGOGHOSSIAN, C. ANDRIEU-SOLER, A. TORRIGLIA* AND F. BEHAR-COHEN*

INSERM U1138, Centre de Recherches des Cordeliers, Université Paris Descartes, Université Pierre et Marie Curie, Paris, France

Abstract—To save energy, the European directives from the Eco-design of Energy Using Products (2005/32/CE) have recommended the replacement of incandescent lamps by more economic devices such as Light Emitting Diodes (LEDs). However, the emission spectrum of these devices is enriched in blue radiations, known to be potentially dangerous to the retina. Recent studies showed that light exposure contributes to the onset of early stages of age-related macular degeneration (AMD). Here, we investigate, in albinos and pigmented rats, the effects of different exposure protocols. Twenty-four hours exposure at high luminance was compared to a cyclic (dark/light) exposure at domestic levels for 1 week and 1 month, using different LEDs (Cold-white, blue and green), as well as fluorocompact bulbs and fluorescent tubes. The data suggest that the blue component of the white-LED may cause retinal toxicity at occupational domestic illuminance and not only in extreme experimental conditions, as previously reported. It is important to note that the current regulations and standards have been established on the basis of acute light exposure and do not take into account the effects of repeated exposure. © 2016 IBRO. Published by Elsevier Ltd. All rights reserved.

Key words: retina, Light Emitting Diodes, phototoxicity, pigmented rats, chronic light exposure.

INTRODUCTION

Artificial light consumes near to 20% of the world electricity production. To save energy, the European directives from the Eco-design of Energy Using Products (2005/32/CE) have recommended the

replacement of incandescent lamps by more economic devices such as Light Emitting Diodes (LED). By 2019, LED will be the major domestic and public light source. LEDs emit mono chromic lights, and the less expensive and currently used method to produce white light from LED is to combine a blue LED with yellow phosphore coverage. The resulting spectrum is enriched in blue radiations, known to be potentially dangerous to the retina (Algvere et al., 2006). The other concerns are the high luminance level and the visual discomfort due to the punctual character of the emitting surfaces.

The role of sunlight exposure in the development and/or aggravation of retinal diseases and particularly age-related macular degeneration (AMD), which is associated with oxidative stress and inflammation, has been disputed for years (Ardeljan and Chan, 2013; Pinazo-Duran et al., 2014; McHarg et al., 2015). Indeed, cumulative light exposure, and particularly retinal exposure is difficult to estimate (Sloney, 2005). However, recently, based on large population studies, light exposure has been clearly recognized as a contributing factor in the appearance of the early stages of AMD (Klein et al., 2007; Sui et al., 2013).

In this context, light exposure must be considered as part of the environmental factors that can influence multiple physiologic processes and potentially impact pathologic retinal aging. The massive conversion from incandescent lights to LED incorporating devices in domestic lighting should be examined in more depth as recommended by the governmental agencies (ANSES report, (Saisine 2008SA0408) French Agency for Food, Environmental and Occupational Health and Safety).

Risk evaluation is based on epidemiologic studies, experimental results and exposure scenarios. But, while extreme acute exposures to high luminance lighting systems are frequently used in various models of light-induced retinal degeneration, few studies have evaluated the effects of different light sources in conditions close to domestic use (Peng et al., 2012; Shang et al., 2014).

In this study, we investigate, in albinos and pigmented rats, the effects of different exposure protocols. Twenty-four hours exposure at high luminance was compared to a chronic cyclic (dark/light) exposure at domestic levels for 1 week and 1 month, using different LEDs (Cold-white, blue and green), as well as fluorocompact bulbs (CFL) and Cold Cathode fluorescent lamps (CCFL) (fluorescent tubes).

*Corresponding authors.

E-mail addresses: alicia.torriglia@inserm.fr (A. Torriglia), francine.behar@gmail.com (F. Behar-Cohen).

Abbreviations: AMD, age-related macular degeneration; BRB, blood retinal barrier; CCFL, Cold Cathode fluorescent lamps; CFL, fluorocompact lamp; ERG, electroretinogram; LE, Long Evans; LED, Light Emitting Diode; ONL, outer nuclear layer; PBS, phosphate-buffered saline; PNA, peanut agglutinin; W, Wistar.

EXPERIMENTAL PROCEDURES

Animals

8-week-old albino Wistar (W) and pigmented Long Evans (LE) rats (Janvier laboratory, Le Genest St Isle, France) were used in these experiments. At least four rats were used per exposure condition and per time point. Rats were maintained on a 12-h/12-h light–dark (LD) cycle at 22 °C at a luminance below 250 lux, for 21 days before light-exposure experiments. All experimental procedures were performed in accordance with the Association for Research in Vision and Ophthalmology (ARVO) statement for the use of animals in Ophthalmic and Vision Research. Experimental procedures were submitted and approved by the local ethics committee European Council Charles Darwin, University Paris Descartes (Authorization N° – 05, Ce5/2012/019, A75-580).

Light sources

We used two types of lighting devices. For exposure to white LED, commercial cold white LED panel generating 2300 lumens during 24 h was used. The LED panel was placed above 8 transparent cages, placed on white surfaces, leaving enough space for air circulation and constant temperature maintenance at 21 °C. The illuminance measured at the rats' eyes position was 6000 lux (Photometre DT-8809A, CEM, China).

For long-term exposure, specific devices were built and characterized by Statice, France (Fig. 1A). Metallic boxes contained rows of LED with a diffuser in order to improve the directional uniformity of the radiation and

avoid punctate sources. Alternatively, CCFL or CFL were uniformly distributed around the metal cages. Each cage was placed in a metallic device that was then placed in a ventilated cupboard allowing for a constant 21 °C temperature control (Fig. 1A). The light intensity was controllable and the distribution of light in the cage was homogenous whatever the rat position. Different types of LEDs were used: cold-white LED (pure white 6300 K), blue LED (royal blue 455–465 nm), and green LED (520–535 nm) (Z-power LED, Seoul Semiconductor, Korea). Exposure intensity was spectrophotometrically measured by Statice.

Exposure protocols

Acute exposure: LE and W rats were maintained in a cyclic light/dark (250 lux, 12 h/12 h) environment for 21 days. The day before light exposure, rats were dark-adapted for 16 h. The next day, pupils were dilated with 1% atropine (Alcon, Norvartis, Rueil Malmaison, France) under dim light, and rats were isolated in separate cages containing enough food for one day. After 24 h of exposure, rats were placed again in a cyclic light/dark (250 lux, 12 h/12 h) environment for 7 days and sacrificed for histology and immunofluorescence analysis. Control rats were submitted to the same pre conditioning protocol but not exposed to light. Different types of light sources and light intensities were used as detailed in Fig. 1B. For cold-white LED, different light intensities were tested from 6000 lux, to 1500, 1000 and 500 lux. Blue and green LEDs were used at 500 lux which is the domestic classic light intensity. CFL was used at 6000 lux and 500 lux, CCFL at 6000 lux. Illuminance was measured at the level of the rat eye.

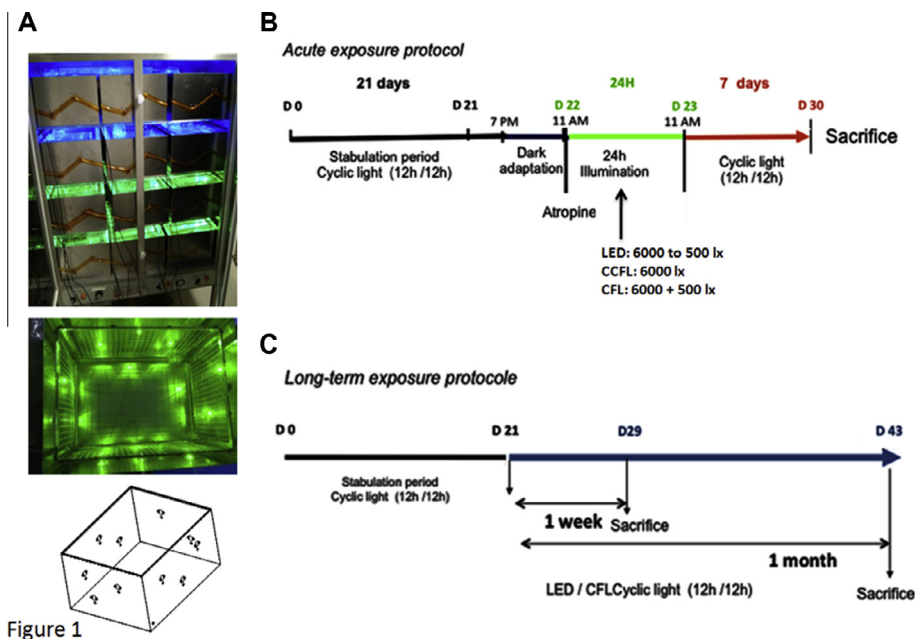


Figure 1

Fig. 1. LED device and exposure protocols. (A) LED containing device: all the walls of the animal's compartment were equipped with LEDs. (B) Acute exposure protocol: rats were kept in the normal cyclic light of the animal facilities for 3 weeks. Before exposure to LEDs on the device seen on panel A, they were dark-adapted and their pupils were dilated with atropin before LED exposure (6000, 1500, 1000 or 500 lx). After 24 h of exposure they were returned to the animal facility for 7 days and then sacrificed. (C) Long term exposure protocol: After the same stabulation period than before, the rats were exposed in the LED device, cyclically (12 h dark/ 12 h light, 500 lx) for one week or 1 month and then sacrificed.

Long-term exposures: Rats (LE and W) were maintained in a cyclic light/dark (250 lux, 12 h/12 h) environment for 21 days, then placed in specific cages for chronic cyclic exposure to different types of light at 500 lux: CFL, white, green and blue LEDs. Animals were sacrificed right after 8 or 28 days of exposure. For the long-term protocol and in order to be as close to domestic light as possible, rat pupils were not dilated.

Histology and photoreceptors quantification

Animals were sacrificed with sodium pentobarbital (> 60 mg/kg, intraperitoneal) and eyes were enucleated. Eyes were oriented (superior/ inferior pole), rinsed in cold PBS for 1 h, transferred to an ascending series of ethanol solutions (70%, 96%, for 2 h) then put in two successive bathes of infiltration resin and ethanol (1:1). Finally, they were embedded in the same resin with catalyzer. 5- μ m-thick sections were placed at 37 degrees for 24 h and then stained with toluidine blue and incubated at 37 degrees for 24 h before microscope observation and photography.

Photoreceptor quantification was done by counting for each retinal section the number of nuclei in the outer nuclear layer (ONL) from the optic nerve each 0.5 mm (0.5, 1, 1.5, 2, 2.5, 3, 3.5 and 4 mm) in both directions (superior and inferior retina). Mosaic pictures were done for masked counting.

Immunofluorescence and TUNEL assay

Freshly enucleated eyes ($n = 3\text{--}4$ per time point) (superior pole tagged with suture) were fixed for 2 h with 4% paraformaldehyde (PAF, Inland Europe, Conflans sur Lanterne, Fr) in $1\times$ phosphate-buffered saline (PBS, Gibco distributed by Life Technologies, Thiais, Val-de-Marne, France), washed with PBS, infiltrated with increased concentrations of sucrose and then, mounted in Tissue Tek O.C.T. (Siemens Medical, Puteaux, Fr).

Immunofluorescence was performed on 10- μ m-thick sections. Cryosections were incubated with different primary antibodies: Rabbit anti GFAP (Dako Agilent Tech, USA), rabbit anti-Iba1 (Cell Signaling, Biorad, France); mouse monoclonal anti-CD68 (ED1) (Santa Cruz, USA), mouse monoclonal anti Rho4D2 (Abcam). Rods and cones were respectively labeled with anti-rhodopsin (Rho4D2, R.S. Molday) and peanut agglutinin (PNA) conjugated with fluorescein isothiocyanate (Sigma). Control sections were incubated with rabbit non-immune serum (Invitrogen, Cergy Pontoise, Fr) or without primary antibodies. The corresponding Alexa-conjugated secondary antibodies (Invitrogen) were used to reveal the primary antibodies. Sections were counterstained with 4,6-diamidino-2-phenylindole (DAPI, Sigma). TUNEL assay was performed on all sections following the manufacturer's instructions (Roche Diagnostics, Mannheim, Germany).

The sections were viewed with a fluorescence microscope (BX51, Olympus, Rungis, Fr) or confocal microscope (LSM 510 laser scanning microscope Zeiss, Carl Zeiss, Le Pecq, Fr) and photographed using

identical exposure parameters for all samples to be compared.

Electroretinograms (ERG)

Full-field ERG responses were recorded before and after the end of light exposure. Rats were dark-adapted for 18 hours and anesthetized by an intramuscular injection of a mixture of ketamine and xylazine. The cornea was desensitized with a drop of oxybuprocaine (Novesine© Novartis Ophthalmics, Basel, Switzerland) and the pupils were dilated with a drop of tropicamide (Tropicamide©, Novartis Ophthalmics). Gold wire ring electrodes were placed on the corneas of both eyes and stainless steel needle electrodes inserted into the forehead served as references electrodes. A needle electrode subcutaneously inserted at the base of the animal tail was used for grounding. All these manipulations were performed under dim red light. Measurements were performed using the commercial Ganzfeld VisioSystem device (Siem Biomedicale, Nîmes, Fr). For scotopic electroretinograms in the dark-adapted state, flash intensities ranged from 0.0003 to 10 cd.s/m². Five flashes of 10 ms per intensity were applied at a frequency of 0.5 Hz for -30 to 0 dB and for 30 ms for 10 cd.s/m² (0 dB). Five responses were averaged. Amplitudes of a-waves (negative waves) were measured from the baseline to the bottom of the a-wave, b-wave amplitudes (positive waves) were measured from the bottom of the a-wave trough to the peak of the b-wave. Implicit times of the a- and b-waves were measured from time of stimulus to peaks. Results were expressed in microvolts (μ V) for amplitudes and milliseconds (ms) for implicit times. The data obtained from each eye belonging to the same experimental group were averaged. We analyzed the variation of each parameter of the ERG before-after light exposure. The a-wave is a negative wave, thus a positive variation is an alteration of the a-wave amplitude. The b-wave is a positive wave, thus a negative variation is an alteration of the b-wave amplitude. When the variation of the implicit time is positive, it also means an alteration of the function.

Statistics

Data are presented as the mean \pm SD. Data were evaluated using R-cran software. Kruskal–Wallis test was done to test for normality ($p = 0.05$), then a post hoc analysis was performed. For a one to one comparison a Mann–Whitney test was done and for a multiple comparison, a Dunn test and a Conover Imann test were performed. $p < 0.05$ was considered as significant.

RESULTS

All light sources induced photoreceptor damage in both pigmented and albino rats after acute exposure at 6000 lux with dilated pupil

The aim of this first protocol was: (1) to compare light sensitivity of pigmented and albino rats to high and low

light intensities, (2) to compare different light sources at high and low intensities (3) to determine the toxic threshold level of LED.

After 24 h of light exposure at 6000 lux, a clinical difference was observed between rats exposed to white LEDs as compared to rats exposed to other light sources. In LED-exposed rats an important edema of the eyelids and the conjunctiva, as well as the face of the animals was observed (not shown).

Under these conditions a significant loss of photoreceptors was observed in the superior retina of both LE and W rats with all types of light sources (Fig. 2A, B). At this light intensity, loss of photoreceptors cells was also observed at a lesser extent in the inferior part of the retina. The loss of cells was significantly less in pigmented (LE) rats as compared to albino (W) rats (not shown). In LE rats, white LED, CCFL and CFL induce similar loss of photoreceptors in the superior retina (Fig. 2A), but in W rats, the most important loss of cells was induced by CCFL (fluorescent tube) (Fig. 2B). Interestingly, W rats seem less sensitive to CFL than to other devices and less sensitive to CFL than LE rats (Fig. 2B).

Immunohistochemistry allowed a more detailed analysis of the retinal damage caused by LED exposure (Fig. 3). In LE rats, macroglial activation was more intense than in W rats with sub retinal glial Müller cell migration (Fig. 3 inset). In W rats, macroglia was less activated but numerous GFAP dendritiform cells were localized in the outer plexiform layer (OPL) and in the sub retinal space (Fig. 3, W-LED asterisks). In both strains, rods (Rho 4D2) and cones (PNA) were severely damaged but while some rods still remained, no cones were left (Fig. 3 Rho4D2 and PNA)). IBA1/ED1-co labeling indicated that an intense inflammatory reaction was present in W illuminated rats with numerous IBA1-positive cells in the inner retina and IBA1/ED1 co-labeled activated cells in the sub retinal space. In LE

rats, the inflammatory reaction was mostly confined to the outer retina where activated round IBA1-positive microglial cells, ED1-positive macrophages and co labeled cells were observed.

Concerning the other lighting devices, immunohistochemistry showed intense activation of glial Müller cells exposed to CCFL or CFL in both pigmented and non-pigmented rats (Fig. 4). The most damaged outer retina with the most intense sub retinal gliosis was seen in Wistar rats exposed to CCFL. With both CCFL and CFL, both rods and cones were altered but with a more intense loss of cones as shown by PNA labeling. An intense inflammatory reaction involving both microglial cells and macrophages was observed in all retinas with a higher infiltration of ED1-positive/IBA1-negative cells, suggesting infiltrating macrophages, in LE rats as compared to albino rats, where the microglial activation was intense (Fig. 4 insets).

At 500 lux, cold-white LED, but not CFL induced photoreceptor damage both in albino and pigmented rats after acute exposure and dilated pupil

The results presented above suggested that pigmented rats were not completely protected from retinal degeneration induced by LEDs as compared to their albino counterpart. We tested then decreasing luminances to detect different sensitivities to light toxicity between the pigmented and the albino strains. Using the same acute protocol (Fig. 2B), the effects of LED light at 500, 1000 and 1500 lux were evaluated on LE and W rats. At 500 lux, which is the recommended light intensity for domestic lighting, CFL did not induce any photoreceptor cells loss, neither in pigmented nor in albino rats at the inferior retina level (Fig. 5, left column). At the superior retina, however, the same dose induced a decrease in the number of photoreceptor's rows when LEDs light was used. With this light source,

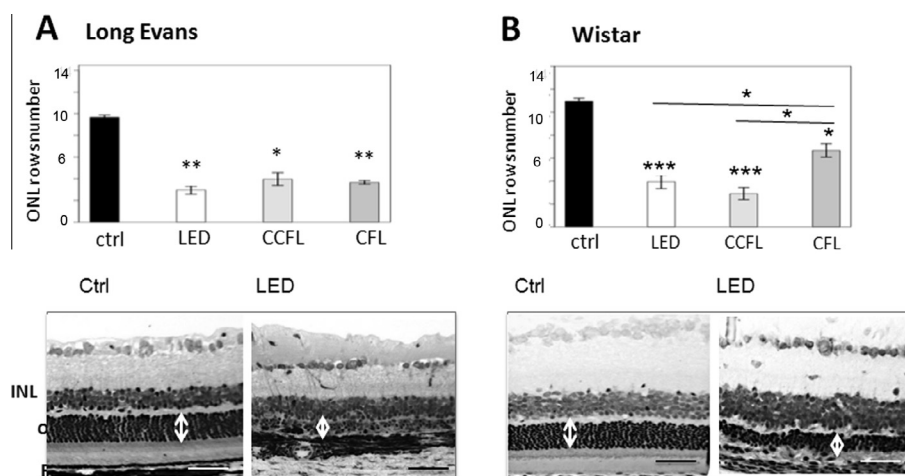


Fig. 2. Retinal degeneration induced in albino Wistar and pigmented Long Evans rats by a single exposure to 6000 lux for 24 h: Wistar or Long Evans rats ($N = 4$) were exposed for 24 h to 6000 lux white light. One week after the exposure the animals were sacrificed as described on Fig. 1B. Afterward, the eyes were fixed, included in paraffin, sectioned and stained with hematoxyline-eosine (lower part of both panels). The photoreceptors' nuclei were counted in the superior and inferior retina. The light was obtained using either a LED, a CCFL or CFL source. (A) Long Evans rats, (B) Wistar rats. (* $p < 0.05$, ** $p < 0.01$, *** $p < 0.001$, SEM were used for graph and SD for statistical work. Significance was evaluated using the Conover-Inan statistical test). In lower images the Scale bar = 50 μm.

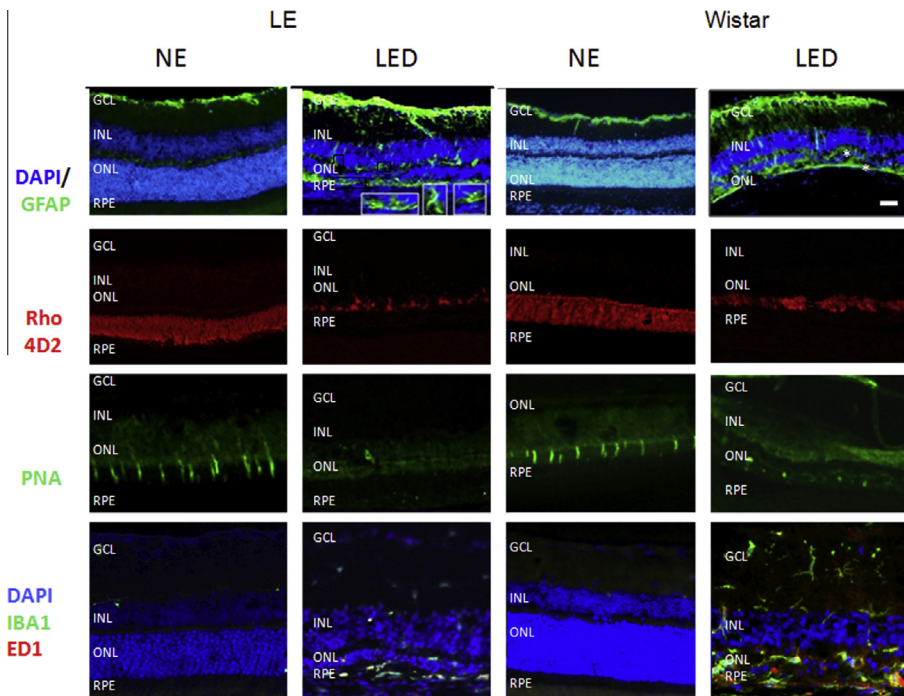


Fig. 3. Modifications induced in GFAP expression, rods (Rho4D2), cones (PNA) and inflammatory cells (IBA1 and ED1) by white LED exposure: Wistar or Long Evans rats ($N = 4$) were exposed for 24 h to white LED light (6000 lux). One week after the exposure, the animals were sacrificed as described on Fig. 1B. Afterward, the eyes were fixed, included in OCT, cryo-sectioned and immunolabeled using different antibodies. NE: retinas from non-exposed animals used as control, LED: retinas from rats exposed to white LEDs. DAPI-GFAP row shows GFAP labeling in green counterstained with DAPI in blue. Insets show details of the Müller cells expansions. Rho4D2 row shows labeling of rods, PNA row labeling of cones. The lower row was labeled with anti-Iba1 in green and anti-ED1 in red, unveiling macrophages and microglia. Cells labeled with both antibodies are seen in yellow. A DAPI counterstained is shown in blue. Scale bar = 20 μm . (For interpretation of the references to color in this figure legend, the reader is referred to the web version of this article.)

a dose-dependent loss of photoreceptor cells was observed after acute illumination of both albino W and pigmented LE rats with dilated pupils (Fig. 5, right column). Only at 1500 lux, inferior retinas of both W and LE were affected with significantly more photoreceptors loss in W as compared LE (Fig. 5, left column). These results clearly show that at the same light intensity, different light sources do not exert the same toxicity: LEDs are more toxic for the retina than CFL. Importantly, in these experiments, pigmented rats also showed light damage at domestic used intensity.

Analysis of the inflammatory reaction by immunofluorescence showed that a LED exposure for 24 h at 500 lux, resulted in an activated macroglia in the superior retina of both LE and W rats as shown by GFAP staining (Fig. 6). In LE rats, GFAP-positive macroglial cells were observed migrating in the outer retina (Fig. 6, inset). Although the decrease in photoreceptors nuclei was higher in W than in LE rats, in LE rats, cones labeled by PNA have been completely lost although some remained in W rats (Fig. 6). The decrease in rod labeling (Rho4D2) followed the same pattern in both types of animals.

At 1500 lux (Fig. 6 right), a more intense damage was observed in both W and LE rats, where a major macroglial activation associated to a complete loss of cones and rods was also observed. Note that although ONL thickness was decreased in W-exposed rats, the total retinal thickness was not decreased due to retinal edema.

The retinal pigment epithelium is also involved

The presence of retinal edema suggested that the blood retinal barrier (BRB) could be damaged. The outer BRB is formed by the tight-junction retinal pigment epithelium that in physiologic conditions do not allow the passage of albumin from the choroid to the retina (Rizzolo, 1997). Breakdown of the retinal pigment epithelial barrier was evaluated by albumin labeling using an anti-rat serum albumin. After 24 h of LED exposure we saw the presence of albumin in the superior retina of both pigmented and albino rats (Fig. 7); some leakage was also seen, in a lesser extent in the inferior retina of albino rats.

Long-term exposure to LED at 500 lux, in cyclic (light/dark) conditions induced retinal damage only in albino rats but not in pigmented rats

Tissue modifications. Next we investigated the retinal effect of different light sources (CFL and LED) and colors (white, blue and green LEDs) after 1 week and 1 month of cyclic exposure at 500 lux without pupil dilation (mimicking long-term domestic lighting). After 1 week of exposure, retinal damage was different in W albinos and LE pigmented rats. In W rats, retinal cell loss following 1 week of exposure was observed only in the superior retina of rats exposed to blue-LEDs (Figs. 8 A and 9A). After 1 month of exposure, all LEDs induced retinal damage in the superior retina, and only blue and

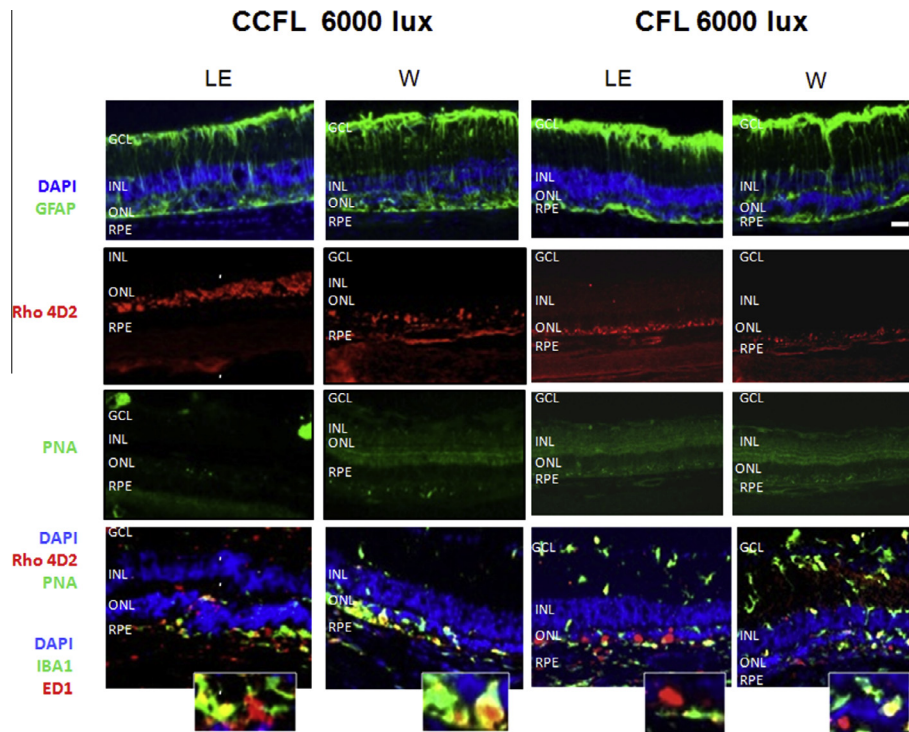


Fig. 4. Modifications induced in GFAP expression, rods, cones and inflammatory cells by exposure to CCFL or CFL: Wistar (W) or Long Evans (LE) rats ($N = 4$) were exposed for 24 h to CCFL or CFL light (6000 lux). One week after the exposure the animals were sacrificed as described on Fig. 1B. Afterward, the eyes were fixed, included in OCT, cryo-sectioned and immunolabeled using different antibodies. Control images for these labeling can be seen on Fig. 3. DAPI-GFAP row shows GFAP labeling in green counterstained with DAPI in blue. Rho4D2 row shows labeling of rods, PNA row labeling of cones. The lower row was labeled with anti-Iba1 in green and anti-ED1 in red, unveiling macrophages and microglia. Cells labeled with both antibodies are seen in yellow. Insets show details of this double labeling. A DAPI counterstained is shown in blue. Scale bar = 20 μm. (For interpretation of the references to color in this figure legend, the reader is referred to the web version of this article.)

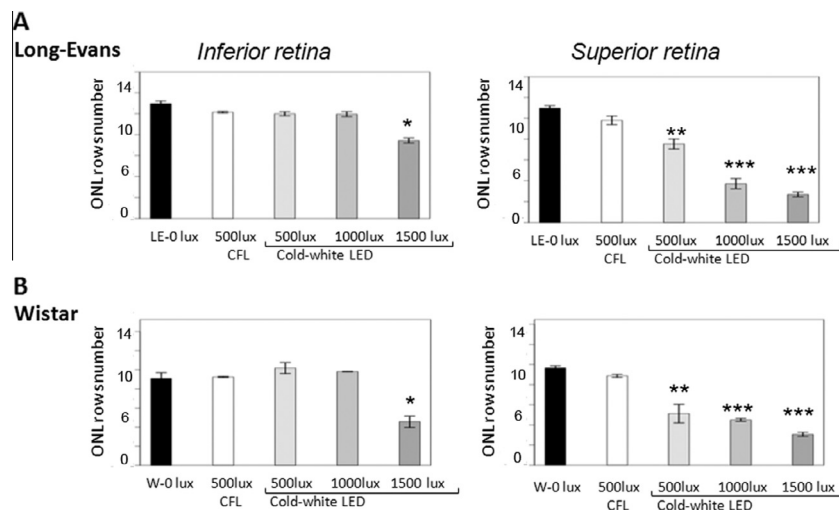


Fig. 5. Retinal degeneration induced in albino Wistar and pigmented Long Evans rats by a single exposure to different luminance of white LED and CFL during 24 h: Wistar or Long Evans rats ($N = 4$) were exposed for 24 h to different luminance of white LED or to CFL 500 lx. One week after the exposure the animals were sacrificed as described on Fig. 1B. Afterward, the eyes were fixed, included in paraffin, sectioned and stained with hematoxyline-eosin (lower part of both panels). The photoreceptors' nuclei were counted in the superior and inferior retina. The light was obtained using either a LED source or a CFL source. (A) Long Evans rats, (B) Wistar rats. (* $p < 0.05$, ** $p < 0.01$, *** $p < 0.001$, SEM were used for graph and SD for statistical work, Significance was evaluated using the Conover-inan statistical test).

green LEDs induced damage also in the inferior retina (Fig. 8B). In contrast, LE-pigmented rats did not present any significant retinal cell loss under these conditions

(Fig. 9A, B) (the number of photoreceptors' nuclei were compared to rats exposed to CFL that had no effect on photoreceptors' number, see Fig. 3). The

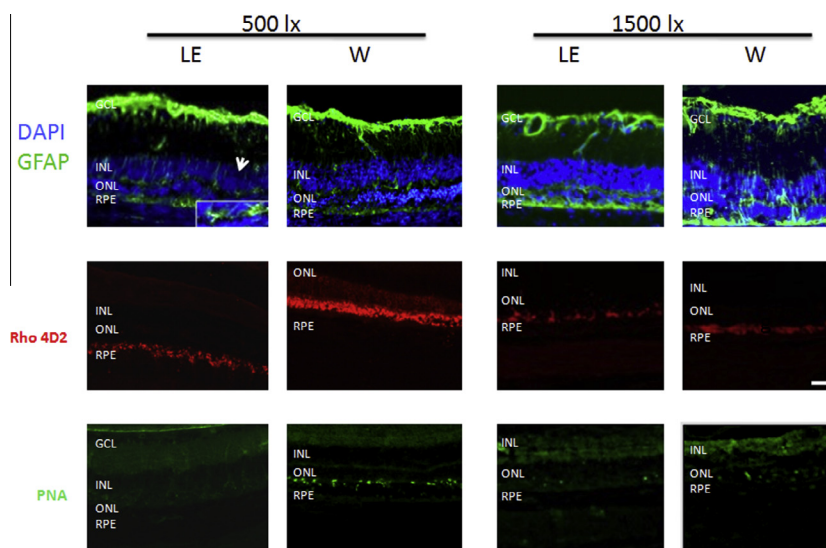


Fig. 6. Modifications induced in GFAP expression, rods and cones by exposure to different luminances of white LED (500 and 1500 lx): Wistar (W) or Long Evans (LE) rats ($N = 4$) were exposed for 24 h to white LED (500 and 1500 lx). One week after the exposure the animals were sacrificed as described on Fig. 1B. Afterward, the eyes were fixed, included in OCT, cryo-sectioned and immunolabeled using different antibodies. Control images for these labeling can be seen on Fig. 3. DAPI-GFAP row shows GFAP labeling in green counterstained with DAPI in blue. Rho4D2 row shows labeling of rods, PNA row labeling of cones. Insets show details of the Müller cells expansions. Scale bar = 20 μm . (For interpretation of the references to color in this figure legend, the reader is referred to the web version of this article.)

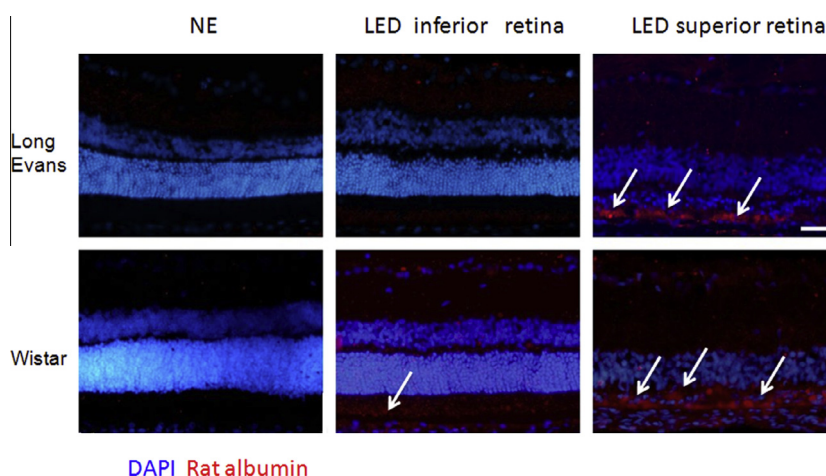


Fig. 7. Leakage of the outer retinal barrier. Wistar or Long Evans rats ($N = 4$) were exposed for 24 h to white LEDs at 1500 lx. One week after the exposure the animals were sacrificed as described on Fig. 1B. Afterward, the eyes were fixed, included in OCT, cryo-sectioned and immunolabeled using anti rat serum albumin. NE, non-exposed control rats; LED, LED-exposed rats. White arrows indicate the regions of leakage. Scale bar = 25 μm .

immunohistochemical analysis of these retinas, exposed to 1-month cyclic illumination, showed a conserved Rho4D2 labeling in LE rats, a decrease of photoreceptors's outer segment in W rats that include a loss or an alteration of cones when exposed to blue or green lights (Fig. 10). Interestingly, the results shown on Fig. 9 and the rhodopsin and cones labeling in Fig. 10 suggested that, using the present protocol, we did not induce any damage to the retina of pigmented rats. However, when analyzing the expression of GFAP it appeared that exposure to green LED did not change the expression of this protein as compared to the control (see Fig. 3), while exposure to white LEDs and blue protein even in LE rats.

Functional modifications. In W and LE rats, we recorded the full-field electroretinograms (ERG, visual function) of both eyes before and after a 1-month of long cyclic illumination to white LEDs at 500 lux. We analyzed, for each ERG parameter, the variation before and after light exposure, noted "delta". As the a-wave is a negative wave, a positive variation represents a decrease of the a-wave amplitude. As the b-wave is a positive wave, a negative variation of the b-wave amplitude. We showed that both scotopic a- and b-waves' amplitudes are impaired by white LED illumination, in albino (W) as well as in pigmented (LE) rats (Fig. 11). In LE, the a-wave (photoreceptors function) deterioration occurred with a little delay when

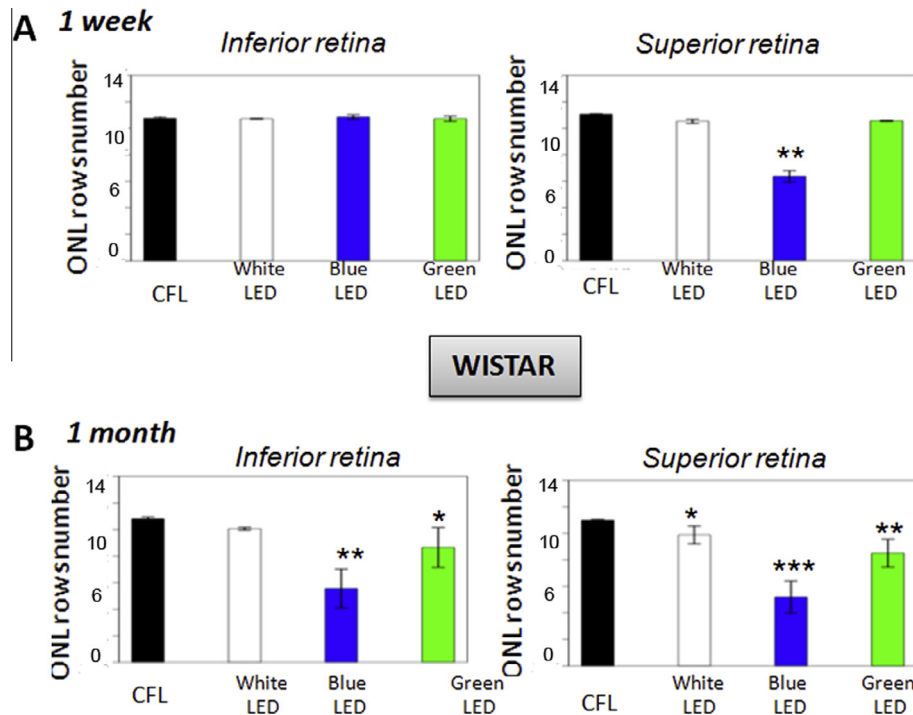


Fig. 8. Retinal degeneration induced in albino Wistar rats by a cyclic exposure (15 h light/12 h dark) to 500 lx of white, blue or green LEDs: Wistar rats ($N = 4$) were exposed cyclically to 500 lx of LED light for 1 week or 1 month. After the exposure the animals were sacrificed as described on Fig. 1C. Afterward, the eyes were fixed, included in paraffin, sectioned and stained with hematoxyline-eosin. The photoreceptors' nuclei were counted in the superior and inferior retina. (A) 1 week of exposure, (B) 1 month of exposure. (* $p < 0.05$, ** $p < 0.01$, *** $p < 0.001$, SEM were used for graph and SD for statistical work. Significance was evaluated using the Conover-Inan statistical test). (For interpretation of the references to color in this figure legend, the reader is referred to the web version of this article.)

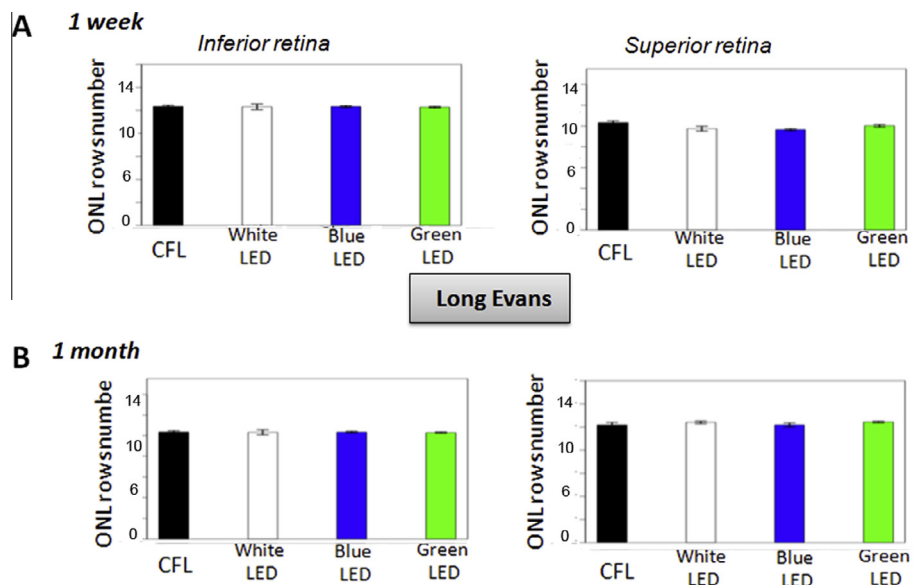


Fig. 9. Retinal degeneration induced in pigmented Long Evans rats by a cyclic exposure (15 h light/12 h dark) to 500 lx of white, blue or green LED or to fluocompact light: Long Evans rats ($N = 4$) were exposed cyclically to 500 lx of LED or fluocompact light for 1 week or 1 month. After the exposure the animals were sacrificed as described on Fig. 1C. Afterward, the eyes were fixed, included in paraffin, sectioned and stained with hematoxyline-eosin. The photoreceptors' nuclei were counted in the superior and inferior retina. (A) 1 week of exposure, (B) 1 month of exposure. (* $p < 0.05$, ** $p < 0.01$, *** $p < 0.001$, SEM were used for graph and SD for statistical work. Significance was evaluated using the Conover-Inan statistical test). (For interpretation of the references to color in this figure legend, the reader is referred to the web version of this article.)

compared to W rats, suggesting that W photoreceptors, were more sensitive than LE's. Whereas, LE b-wave (inner retina function) is slightly less deteriorated than W

rats's b-wave (non significant trend, however). Implicit times of both a- and b-waves are not modified by this illumination protocol, neither in W nor in LE rats.

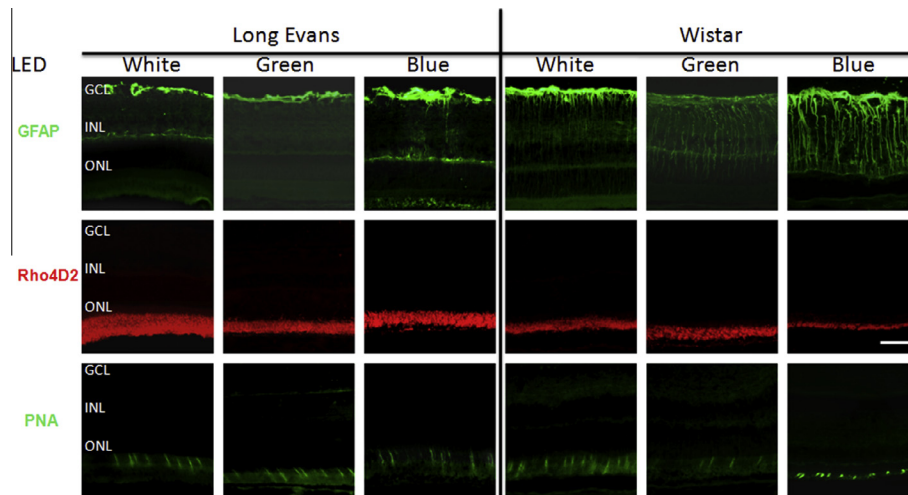


Fig. 10. Modifications induced in GFAP expression, rods and cones by the exposure of a cyclic with LED (500 lx) for one month. Wistar or Long Evans rats ($N = 4$) were exposed cyclically to 500 lx of white, green or blue LED light for 1 month. After the exposure, the animals were sacrificed as described on Fig. 1C. Afterward, the eyes were fixed, included in OCT, cryo-sectioned and immunolabeled using different antibodies. Control images for these labeling can be seen on Fig. 3. GFAP row shows GFAP labeling in green. Rho4D2 row shows labeling of rods, PNA row shows labeling of cones. Scale bar = 35 μm . (For interpretation of the references to color in this figure legend, the reader is referred to the web version of this article.)

It is interesting to note that, following this 1-month long cyclic illumination protocol, ONL thickness was slightly reduced only in the W superior retina, while it was unaltered in W inferior and LE superior and inferior retinas; whereas, at the same time, macroglia was already activated, and ERG a- and b- waves were already impaired.

DISCUSSION

The aim of this study was to compare different commercial light sources, available for domestic lighting on different animal strains, pigmented and non-pigmented rats and with different exposure scenarios. Different conditions of pupil dilation, as well as different exposure conditions were compared. Our purpose was to reproduce both the acute and extreme conditions used in light-induced retinal damage models and the domestic lighting conditions, which are the more representative of potential toxic effects for humans. Indeed, many studies have extensively analyzed the effect of acute exposure to high light intensity in order to decipher the mechanisms of light-induced retinal toxicity (Stone et al., 1999; Wenzel et al., 2005; Chahory et al., 2010; Organisciak and Vaughan, 2010), but much less experiments have been conducted to analyze the risks of new LED lighting systems in domestic lighting conditions (Shang et al., 2014; Jaadane et al., 2015). Recently, we performed an extended analysis of the mechanisms of LED-induced retinal cell toxicity on albino rats, showing that unexpectedly, not only apoptosis was induced but also necrotic cell death, particularly with blue LEDs (Jaadane et al., 2015). This necrotic death triggered an important inflammatory response as observed in our experiments, even at domestic light intensity on albino rats. The present study was not designed to study mechanisms but mostly to define the toxicity threshold condi-

tions of different LEDs in occupational and domestic conditions.

As expected, at high illuminance, i.e. 6000 lux, with dilated pupils, retinal damage was observed equally with all light sources, CCFL, CFL and white LEDs, all induced a significant reduction in the photoreceptor layer thickness, intense macroglial reaction with sub retinal proliferation, rods segment fragmentation, loss of cones and intense microglial activation and macrophages infiltration at 8 days after light exposure. Inflammatory reaction seemed more diffuse all over the retina in LED-exposed W rats as compared to LE rats but this was not specifically quantified. This could be related to the necrotic cell death observed when albino rats were exposed to blue-light containing LEDs (Jaadane et al., 2015) or to an enhanced inflammatory reactivity of this particular rat strain. More surprisingly, after 24hrs of continuous exposure of rats with dilated pupils, to white-cold LED at 500 lux, a significant reduction of ONL thickness was found not only in albinos but also, to a lesser extent in pigmented rats. Obviously, in physiologic conditions, when exposed to light, pupil constriction very efficiently reduces retinal exposure, protecting from toxicity (Slone, 2005). This was confirmed by the absence of ONL reduction when pigmented rats were submitted to same lighting conditions but without dilation of the pupil (Figs. 8 and 9). It is important to note that in dilated conditions, at the same illuminance, CFL did not cause any damage neither in the albino nor in the pigmented rat, demonstrating that different light sources do not exert the same potential retinal risk. Reduction of the photoreceptor layer was correlated to the illuminance produced by the white-cold LEDs demonstrating a dose-response toxic effect. The role of blue radiations is well recognized and have been also confirmed using blue LEDs in albino rats, where intense cone toxicity was shown at 200-lux illuminance measured on the rat cornea

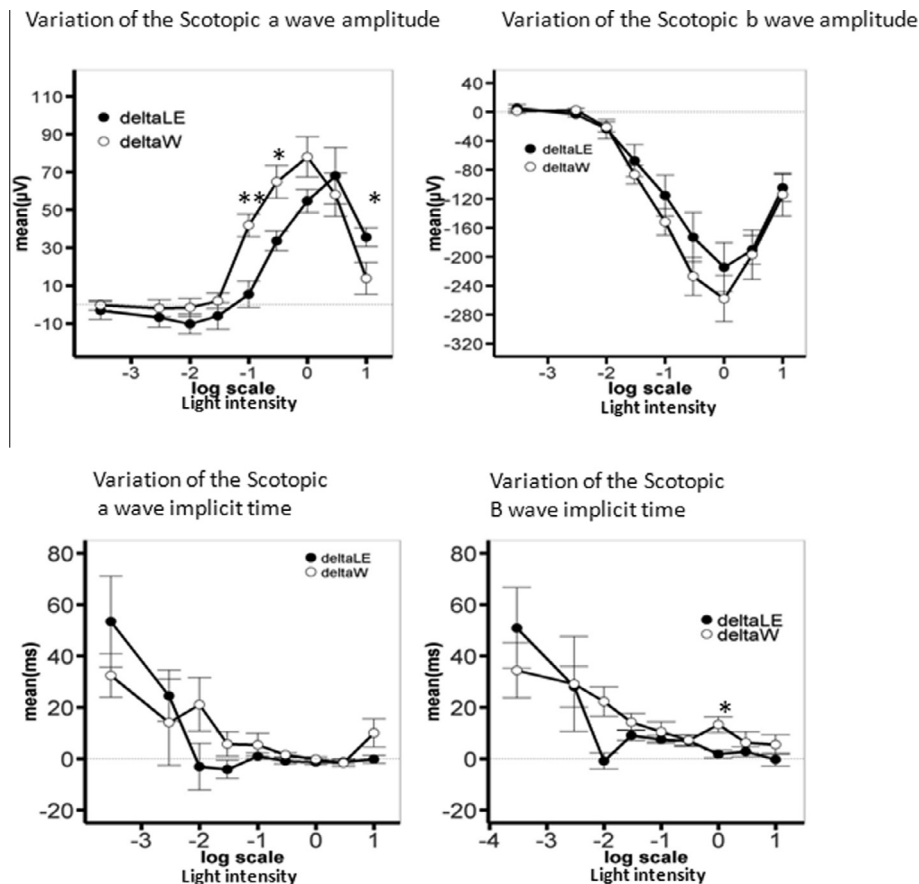


Fig. 11. Modifications induced in scotopic full-field electroretinogram by the exposure of a cyclic with LED (500 lx) for one month. The scotopic amplitudes of a- and b-waves and implicit times of the same ERG waves were represented as the delta (variation) between exposed and non-exposed animals. Scotopic ERG were recorded before and after illumination. Following an overnight dark-adaptation, animals were anaesthetized and their pupils dilated; stimuli consisted of light flashes of nine increasing intensities delivered through a Ganzfeld bowl (0.000–10 cd.s.m² here expressed in log scale intensities, Siem Biomedicale). Responses to five flashes per intensity were averaged (Visiosystem software). Mean variation of the a- (left column) and b-waves (right column) amplitudes (first row) and implicit times (second row) were compared between albino Wistar (W, white dots) and pigmented (LE, black dots) rats. As the a-wave is a negative wave, a positive variation is an alteration of the a-wave amplitude. As the b-wave is a positive wave, a negative variation is an alteration of the b-wave amplitude. Here, both scotopic a- and b- waves' amplitudes are impaired by white LED illumination, in albino (W) as well as in pigmented (LE) rats. Significance of the difference between W and LE variation of the a- and b-waves amplitudes was evaluated using the Mann–Whitney non-parametric test. Asterisk indicate significant differences * $p < 0.05$, ** $p < 0.005$. The a- and b-waves implicit times were not significantly affected by this illumination protocol.

(Ortin-Martinez et al., 2014). Here, blue LEDs at 500-lux illuminance were toxic after 24 h of continuous exposure even in pigmented not dilated pupil rats, which questions the potential effects of domestic blue light on human retinas, commonly used for decoration purposes.

Acute LED-induced damage were shown by several groups. In 2001, Dawson showed that the direct exposure of monkey retinas to a blue LED (460 nm, corneal irradiance over 10 J/cm²) induced macular lesions similar to those induced by an argon laser (458 nm) (Dawson et al., 2001). Macular lesions were also observed in monkey by Ueda et al. after direct exposure to a 465 nm LED (Ueda et al., 2009). More recently, Mukai et al. exposed monkey retina to LED contact lens for 8 h at an illuminance of 7000 lux, observing both morphologic and functional changes on ERG and spectral domain-OCT, that corresponded to intracellular vacuolization and irregularity of the lamellar structure of segments. Interestingly the ERG changes were transitory and returned to normal values 14 days after the experiments (Mukai et al., 2012).

Extrapolation of acute light exposure to mid and long terms is therefore questionable and whether successive transitory damage may cause long term toxicity remains to be demonstrated.

Only one study was conducted to specifically answer the question of repeated LED exposure toxicity on albino rats. Albino rats were dark-adapted for 14 days and then submitted to 750-lux white LED cyclic exposure for 28 days. Under such conditions, severe retinal damage was observed associating necrotic and apoptotic cell death (Shang et al., 2014). Our experiments confirm these observations using cyclic exposure of young albino Wistar rats to white LED, without pupil dilation and without extensive dark adaptation. To our knowledge, this is the first study comparing cyclic dark/light long-term exposure to white, blue and green LEDs, conducted also on pigmented rats without pupil dilation. Interestingly, as compared to albino rats, no significant morphological retinal damage was observed in pigmented animals under these lighting conditions. However, in addition to impaired retinal function, some other oxidative

stress markers, like GFAP overexpression appear, suggesting that infra clinical oxidative stress, cumulated over years, could induce other types of retinal alterations, not examined in these experiments, and difficult to detect in a relevant animal experiment.

Many factors influence retinal exposure and retinal toxicity, including retinal pigment epithelium pigmentation, pupil diameter, geometry of the face and the nature of the light radiations, including its spectrum, its intensity, the exposure sequence and timing of exposure (Youssef et al., 2011; Hunter et al., 2012). Age, lens color (increasing yellow pigment with aging), stress-induced steroids, pre-existing retinal pathology also influence light sensitivity. Extrapolation of animal experiments are challenging and particularly, rats that do not have a macula and therefore do not recapitulate human retina characteristics. But, comparisons were made in this study in a very controlled manner which allow compare the effects of different light sources. It shows that at the same illuminance and under similar conditions, white, blue and green LEDs provoke retinal damage, while CFLs do not. They also highlight once more, the toxicity of blue light and particularly of blue-LEDs.

Taken together these data suggest that the blue component of the white-LED may cause retinal toxicity at occupational domestic illuminance and not only in extreme experimental conditions, as previously suspected (Behar-Cohen et al., 2011; van Norren and Gorgels, 2011). It is important to note that the current regulations and standards have been established on the base of acute light exposure and do not take into account the effects of repeated exposure (Jarrett and Boulton, 2012; Protection, 2013). Moreover, no clear surrogate marker of light-induced retinal stress is used to detect sub-clinical retinal damage, that with time, could induce a different type of toxicity such as the one seen in AMD (Marquioni-Ramella and Suburo, 2015).

Since LEDs will very soon become the predominant light source in our domestic environment, it becomes urgent to establish a safe way to use them in the short and long term.

Authors' involvement

AK made most of the experiments, MB performed the ERG, DM and IJ made some of the immunostaining experiments, LJ and RL gave technical assistance, CAS and FBC conceived the experiments. AK, MB, EP, AT and FBC wrote the paper.

Acknowledgments—This work was supported by the region Ile de France, grant to FBC and AK and by ADEME, Retinaled grant to IJ and AT.

REFERENCES

- Algvere PV, Marshall J, Seregard S (2006) Age-related maculopathy and the impact of blue light hazard. *Acta Ophthalmol Scand* 84:4–15.
- Ardeljan D, Chan CC (2013) Aging is not a disease: distinguishing age-related macular degeneration from aging. *Prog Retin Eye Res* 37:68–89.
- Behar-Cohen F, Martinsons C, Vienot F, Zissis G, Barlier-Salsi A, Cesarini JP, Enouf O, Garcia M, Picaud S, Attia D (2011) Light-emitting diodes (LED) for domestic lighting: any risks for the eye? *Prog Retin Eye Res* 30:239–257.
- Chahory S, Keller N, Martin E, Omri B, Crisanti P, Torriglia A (2010) Light induced retinal degeneration activates a caspase-independent pathway involving cathepsin D. *Neurochem Int* 57:278–287.
- Dawson W, Nakanishi-Ueda T, Armstrong D, Reitze D, Samuelson D, Hope M, Fukuda S, Matsuishi M, Ozawa T, Ueda T, Koide R (2001) Local fundus response to blue (LED and laser) and infrared (LED and laser) sources. *Exp Eye Res* 73:137–147.
- Hunter JJ, Morgan JJ, Merigan WH, Sliney DH, Sparrow JR, Williams DR (2012) The susceptibility of the retina to photochemical damage from visible light. *Prog Retin Eye Res* 31:28–42.
- Jaadane I, Boulenguez P, Chahory S, Carre S, Savoldelli M, Jonet L, Behar-Cohen F, Martinsons C, Torriglia A (2015) Retinal damage induced by commercial light emitting diodes (LEDs). *Free Radic Biol Med* 84:373–384.
- Jarrett SG, Boulton ME (2012) Consequences of oxidative stress in age-related macular degeneration. *Mol Aspects Med* 33:399–417.
- Klein R, Klein BE, Knudtson MD, Meuer SM, Swift M, Gangnon RE (2007) Fifteen-year cumulative incidence of age-related macular degeneration: the Beaver Dam Eye Study. *Ophthalmology* 114:253–262.
- Marquioni-Ramella MD, Suburo AM (2015) Photo-damage, photo-protection and age-related macular degeneration. *Photochem Photobiol Sci* 14:1560–1577.
- McHarg S, Clark SJ, Day AJ, Bishop PN (2015) Age-related macular degeneration and the role of the complement system. *Mol Immunol* 67:43–50.
- Mukai R, Akiyama H, Tajika Y, Shimoda Y, Yorifuji H, Kishi S (2012) Functional and morphologic consequences of light exposure in primate eyes. *Invest Ophthalmol Vis Sci* 53:6035–6044.
- Organisciak DT, Vaughan DK (2010) Retinal light damage: mechanisms and protection. *Prog Retin Eye Res* 29:113–134.
- Ortin-Martinez A, Valiente-Soriano FJ, Garcia-Ayuso D, Alarcon-Martinez L, Jimenez-Lopez M, Bernal-Garro JM, Nieto-Lopez L, Nadal-Nicolas FM, Villegas-Perez MP, Wheeler LA, Vidal-Sanz M (2014) A novel in vivo model of focal light emitting diode-induced cone-photoreceptor phototoxicity: neuroprotection afforded by brimonidine, BDNF, PEDF or bFGF. *PLoS One* 9:e113798.
- Peng M-L, Tsai C-Y, Chien C-L, Hsiao JC-J, Huang S-Y, Lee C-J, Lin H-Y, Wen Y-C, Tseng K-W (2012) The influence of low-powered family LED lighting on eyes in mice experimental model. *Life Sci J* 9:477–482.
- Pinazo-Duran MD, Gallego-Pinazo R, Garcia-Medina JJ, Zanon-Moreno V, Nucci C, Dolz-Marco R, Martinez-Castillo S, Galbis-Estrada C, Marco-Ramirez C, Lopez-Galvez MI, Galarreta DJ, Diaz-Llopis M (2014) Oxidative stress and its downstream signaling in aging eyes. *Clin Interv Aging* 9:637–652.
- Protection ICoN-IR (2013) ICNIRP Guidelines on limits of exposure to incoherent visible and infrared radiation. *Health Phys* 105:74–96.
- Rizzolo LJ (1997) Polarity and the development of the outer blood-retinal barrier. *Histol Histopathol* 12:1057–1067.
- Shang YM, Wang GS, Sliney D, Yang CH, Lee LL (2014) White light-emitting diodes (LEDs) at domestic lighting levels and retinal injury in a rat model. *Environ Health Perspect* 122:269–276.
- Sliney DH (2005) Exposure geometry and spectral environment determine photobiological effects on the human eye. *Photochem Photobiol* 81:483–489.
- Stone J, Maslim J, Valter-Kocsi K, Mervin K, Bowers F, Chu Y, Barnett N, Provis J, Lewis G, Fisher SK, Bisti S, Gargini C, Cervetto L, Merin S, Peer J (1999) Mechanisms of photoreceptor death and survival in mammalian retina. *Prog Retin Eye Res* 18:689–735.
- Sui GY, Liu GC, Liu GY, Gao YY, Deng Y, Wang WY, Tong SH, Wang L (2013) Is sunlight exposure a risk factor for age-related macular degeneration? A systematic review and meta-analysis. *Br J Ophthalmol* 97:389–394.

- Ueda T, Nakanishi-Ueda T, Yasuhara H, Koide R, Dawson WW (2009) Eye damage control by reduced blue illumination. *Exp Eye Res* 89:863–868.
- van Norren D, Gorgels TG (2011) The action spectrum of photochemical damage to the retina: a review of monochromatic threshold data. *Photochem Photobiol* 87:747–753.
- Wenzel A, Grimm C, Samardzija M, Reme CE (2005) Molecular mechanisms of light-induced photoreceptor apoptosis and neuroprotection for retinal degeneration. *Prog Retin Eye Res* 24:275–306.
- Youssef PN, Sheibani N, Albert DM (2011) Retinal light toxicity. *Eye (Lond)* 25:1–14.

(Accepted 3 October 2016)
(Available online 14 October 2016)